

Patient Name \_\_\_\_\_

Date \_\_\_\_\_

**CLINICAL INDICATIONS**

- ☐ Entropion  
☐ Trichiasis without Entropion

**PROCEDURE**

- ☐ Right Eye  
☐ Left Eye

**ASSESSMENT**

Right Eye

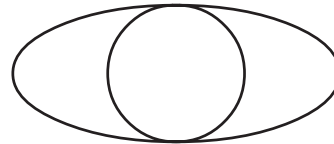
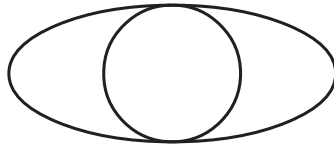
Left Eye

- |                          |                                  |                          |
|--------------------------|----------------------------------|--------------------------|
| <input type="checkbox"/> | Distichiasis                     | <input type="checkbox"/> |
| <input type="checkbox"/> | Metaplastic Eyelashes            | <input type="checkbox"/> |
| <input type="checkbox"/> | Trichiasis without Entropion     | <input type="checkbox"/> |
| <input type="checkbox"/> | Pseudo-Trichiasis with Entropion | <input type="checkbox"/> |

**TECHNIQUE**

The patient was brought into the examination room and placed in an upright position behind the biomicroscope. One drop of proparacaine 0.5% was placed into the eye followed by one drop of topical antibiotic solution. The eyelid was inspected microscopically and the misdirected eyelash or eyelashes were identified. Removal was accomplished by grasping the eyelash with cilia forceps as it exited the follicle and mechanically pulling the eyelash out of the follicle. This procedure was repeated as necessary for each misdirected eyelash. After all misdirected eyelashes were removed, an additional drop of topical antibiotic solution was placed into the eye.

Right Eye



Left Eye

**NARRATIVE**

Cornea \_\_\_\_\_  
Eyelids \_\_\_\_\_  
Eyelashes \_\_\_\_\_

**DISCHARGE**

- ☐ The patient tolerated the procedure well and was discharged in good condition.  
☐ Instructions were given to call the office if there was any pain or discomfort after the procedure.

Doctor's Signature \_\_\_\_\_