

CONJUNCTIVAL FOREIGN BODY REMOVAL

Operative Report

Patient Name _____

Date _____

CLINICAL INDICATIONS

- Conjunctival Foreign Body
- Conjunctival Concretions

INSTRUMENTS

- Forceps
- Cotton-Tipped Applicator
- #25 or #27 Gauge Needle
- Foreign Body Removal Spud

ASSESSMENT

- | Right Eye | | Left Eye |
|--------------------------|--------------------------------|--------------------------|
| <input type="checkbox"/> | Single Foreign Body | <input type="checkbox"/> |
| <input type="checkbox"/> | Multiple Foreign Bodies | <input type="checkbox"/> |
| <input type="checkbox"/> | Superior Palpebral Conjunctiva | <input type="checkbox"/> |
| <input type="checkbox"/> | Bulbar Conjunctiva | <input type="checkbox"/> |
| <input type="checkbox"/> | Inferior Palpebral Conjunctiva | <input type="checkbox"/> |

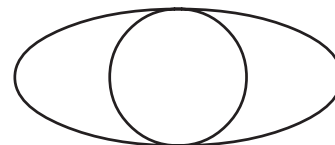
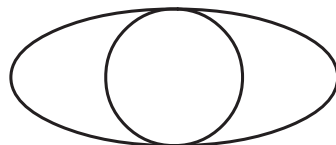
PROCEDURE

- Superficial Removal - CPT Code 65205
- Embedded Removal - CPT Code 65210

TECHNIQUE

- The patient was brought into the examination room and placed in an upright position behind the biomicroscope. The conjunctiva was inspected microscopically and the foreign body was identified. The superficial foreign body was removed from the conjunctiva by forceful irrigation with sterile saline solution.
- The patient was brought into the examination room and placed in an upright position behind the biomicroscope. The conjunctiva was inspected microscopically and the foreign body was identified. Using small strokes tangential to the plane of the eyelid, a sterile cotton-tipped applicator moistened with sterile saline was used to dislodge the foreign body.
- The patient was brought into the examination room and placed in an upright position behind the biomicroscope. One drop of proparacaine 0.5% was placed into the eye followed by one drop of topical antibiotic solution. The embedded foreign body was removed from the conjunctiva and any residual particulate matter was also removed. No sign of globe perforation was evident.

Right Eye



Left Eye

- An antibiotic ointment was placed in the eye and the eye was patched.
- An antibiotic solution was placed in the eye and a bandage contact lens was applied.

DISCHARGE

- The patient tolerated the procedure well and was discharged in good condition.
- Instructions were given to call the office if there was any pain or discomfort after the procedure.

Doctor's Signature _____